


Australian Society  
of Orthodontists



University of Sydney



## Impacted & Ectopic Canines

*Creating Brighter Futures*

# Impacted & Ectopic Canines

## Incidence

An **ectopic tooth** is defined as a tooth that is following an abnormal eruption path whereas an **impacted tooth** is a tooth that is unable to erupt without assistance and is usually associated with an ectopic path of eruption.

The maxillary canine is second only to the mandibular third molar in its frequency of impaction<sup>1-3</sup>. Maxillary impacted canines occur in approximately 1-2% of the population. Mandibular canine impaction occurs less commonly at 0.35%<sup>4-7</sup>. Impacted canines are found palatally in 85% of cases and buccally in 15% of cases and are twice as common in females<sup>7-9</sup>.

## Aetiology

Impacted canines are mostly asymptomatic and often lack an obvious cause of impaction. The precise aetiology of the impaction is unknown, but a number of multi-factorial influencing factors have been suggested<sup>10</sup>. These are best categorised as localised and generalised and are listed in Table 1<sup>1,11</sup>. The most common theories regarding the aetiology of maxillary canine impaction include the guidance and the genetic theories<sup>1</sup>.

Maxillary canines have the longest path of eruption of all the permanent teeth. Normally their inclination relative to the midline increases mesially until the maximum angle is reached at approximately 9 years of age<sup>12</sup>. After this age, the axial alignment becomes more vertical with horizontal movement of the cusp in a distal direction<sup>12</sup>.

Broadbent first coined the expression "ugly duckling" to describe the stage of development associated with the distal flaring of the maxillary lateral incisor crowns and mesial tip of the roots as the permanent canines descend down the distal surface of the lateral incisor root<sup>13</sup>. The lateral incisors upright later when the permanent maxillary canines have erupted past the apical half of the lateral incisor root and are closer to emerging into the mouth.

The guidance theory proposes that the canine erupts along the distal surface of the lateral incisor root, which serves as a guide. If the erupting canine misses making contact with the tip of the lateral incisor root it continues to move more mesially into a palatally 'impacted' position. This theory is supported by the increased incidence of canine impactions associated with peg laterals, which have slightly shorter roots, or congenitally missing lateral incisors<sup>14</sup>. Becker and colleagues also reported a greater likelihood of palatal impaction, 2.4 times the normal rate, when there was an absent or peg maxillary lateral incisor present<sup>15,16</sup>. More recently it appears that the presence of the maxillary lateral incisor roots with a normal root length, formed at the correct time is an important variable to favourable maxillary canine eruption<sup>11</sup>.

The genetic theory associates an increased likelihood of maxillary canine impaction with the presence of various dental anomalies. Baccetti and colleagues reported that palatal displacement of maxillary canines demonstrated significant association with aplasia of second premolars, small sized maxillary lateral incisors, infraocclusion of primary molars and enamel hypoplasias<sup>17</sup>. Peck and Peck described 5 major factors that support the genetic theory:

1. Prevalence of other dental anomalies in patients with palatally impacted canines
2. Bilaterally occurring palatally impacted canines
3. The sexual dimorphism demonstrated by the prevalence of impacted canines suggests possible involvement of the sex chromosomes
4. The familial trend of impacted or ectopic canines
5. Different racial prevalence

More recently, segregation analysis studies examining the genetic aetiology of ectopic canines in twins have reported an autosomal-dominant trait with incomplete penetrance. 85% of 3-generational families included in the study demonstrated an obligate carrier with normal phenotype, suggesting impacted canines will skip a generation<sup>18</sup>.

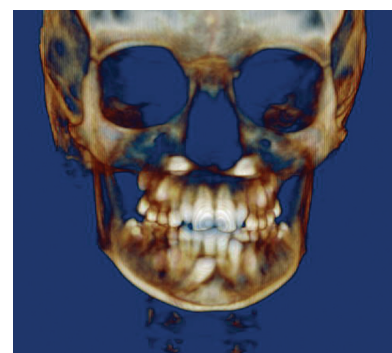


Figure 1: Cone beam image of patient with impacted canines. These can be manipulated in all planes of space to assess the precise location of the impacted tooth and potential damage to the adjacent teeth.

## Colgate CARE COLUMN

Colgate, in partnership with the Australian Dental Association, has launched its 'Brush Night And Day' Campaign to urge Australians to brush their teeth twice a day, to avoid detrimental health and financial consequences. The campaign was launched on the back of recent research which shows that although 68% of people are aware they should be brushing their teeth twice a day, the majority are failing to do so.

The campaign message is simple; brushing night and day with fluoride toothpaste is the most effective way of preventing tooth decay and maintaining good dental health.

Oral health education is important to Colgate and our Bright Smiles, Bright Futures programme provides oral health education kits for pre-school and 8-9 year old children.

These kits are available to oral health professionals as well as teachers. For more information visit: [www.colgatebsbf.com.au](http://www.colgatebsbf.com.au) and to order a free kit phone 1800 075685.



## Diagnosis and Localisation

Ectopic and impacted canines can be diagnosed by a combination of clinical and radiographic features. These include:

- The delayed eruption of one or more of the permanent canines after 14 years of age
- A generalised delay in eruption of all teeth or a disruption from the normal eruption sequence
- Prolonged retention of a primary canine
- Absence of a canine bulge on palpation of the buccal alveolus
- Ability to palpate a canine bulge ectopically such as on the palate
- Presence of excessive distal tipping of lateral incisor with or without rotations, particularly if this persists
- Apexification of the canine is complete yet it remains unerupted
- Greater than 6 months since eruption of the contra-lateral canine.
- Radiographic inclination of the canine to the vertical exceeding 25° and overlapping of the canine crown with the root of the permanent lateral incisor<sup>7, 19</sup>.

An early diagnosis is the key to preventing complications occurring as a result of canine impaction.

Ericson and Kurol demonstrated that 29% of patients were found not to have palpable canines in the buccal alveolar region at the age of 10 years. This reduced to 5% at the age of 11 and 2% at the age of 12 years. They concluded that detection of possible impaction may be evident by 9 years of age. It is vital that palpation for the presence of the canines in the buccal vestibular regions should be conducted for all children from the age of 8<sup>20, 21</sup>.

In addition to palpation for the canine bulge, clinicians should be aware of abnormally positioned or excessively flared lateral maxillary incisors, which often indicate close approximation of an impacted canine to the incisor root<sup>20, 22</sup>. Specific investigation into potential root resorption of these flared teeth should be considered.

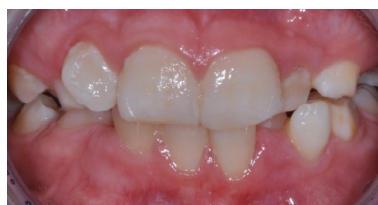

Figure 2: Excessively flared lateral incisor can indicate an impacted canine interfering with the root of the lateral incisor and may be associated with root resorption.

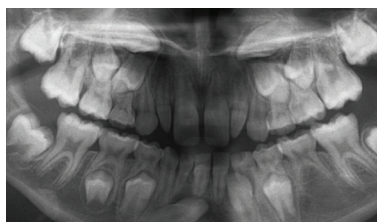

Figure 3: OPG demonstrating impacted maxillary and mandibular canines. Note the presence of maxillary peg lateral incisors. Further radiographs would be required to precisely locate these canines and assess potential root resorption to teeth adjacent to the canines.

Radiographs are recommended for diagnostic purposes where there is asymmetry on palpation, or pronounced difference in canine eruption between left & right sides and where the lateral incisor is excessively proclined or tipped distally<sup>7</sup>. It is recommended to either take an OPG or intra-oral radiographs using different angulations, or alternatively a cone beam scan may be utilised, particularly if root resorption is suspected.

## Sequelae of Impaction

Most impacted canines are asymptomatic and are often diagnosed during routine dental or orthodontic examination. While an impacted canine may exist without causing any side-effects, there is the potential for severe sequelae to result. Therefore early diagnosis, consistent monitoring and management of ectopic canines is important.

The major concern is potential root resorption of the adjacent teeth, with severe resorption involving the pulp of the adjacent teeth having been shown to occur in children as young as 9 years of age<sup>23</sup>. In their radiographic study, Ericson and Kurol found that root resorption to the adjacent incisors occurred in 12.5% of cases in children between 10-13 years of age<sup>8</sup>. A 4:1 ratio was found in the likelihood for root resorption occurring when comparing girls to boys, although this was not supported in a later CT study<sup>23, 24</sup>. When examined by CT imaging, 48% of children were found to have some degree of root resorption<sup>23</sup>. This was twice the incidence diagnosed using intra-oral radiographs, demonstrating the gross underestimation of root resorption using conventional radiographic techniques. While most of this resorption will not be significant some will become clinically relevant hence the importance of early diagnosis and interceptive management.

## Management - Interceptive treatment

When diagnosed early, the eruption path of the impacted canine may be improved by interceptive treatment. In 1988, Ericson and Kurol demonstrated that extraction of a retained deciduous canine could improve the angulation and eruption path of an ectopic canine<sup>2</sup>. Their study demonstrated that after early extraction of the deciduous canine 78% of ectopic canines reverted to a normalised path of eruption. The likelihood of improved angulation was correlated to the age of the patient (approximately 11 years or younger) and the degree of overlap of the canine over the root of the adjacent lateral incisor. 91% of canines which originally overlapped the adjacent lateral incisor root by less than half normalised, while this was reduced to 64% for canines which overlapped the lateral incisor by more than half of the root (Figure 4). Based on their findings, they recommend reassessing alignment of the canine 6 monthly. If no change is detectable after 12 months the tooth is unlikely to normalise and further intervention is required<sup>2</sup>.

More recently, early extraction of both the deciduous canine and deciduous first molar have been suggested, based on research demonstrating favourable eruption of 97% of ectopic canines<sup>26</sup>. Other forms of interceptive treatment include opening space for the ectopic tooth and use of an RME to expand the arch. Application of distalising forces using cervical pull headgear, in addition to extracting the deciduous canine, have also been found to improve the likelihood of normalising the path of eruption compared to cases where only the deciduous canine was extracted<sup>27-29</sup>.

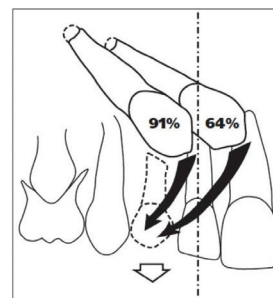


Figure 4: The likelihood of impacted canines erupting without further intervention following extraction of the deciduous canine is dependent on the age of the patient and whether it crosses the midline of the lateral incisor.

Table 1 - Aetiological factors associated with impacted canines

### LOCALISED

- Tooth size-arch length discrepancies
- Failure of the primary canine root to resorb
- Prolonged retention or early loss of the primary canine
- Ankylosis of the permanent canine
- Cyst or neoplasm
- Dilaceration of the root
- Absence of the maxillary lateral incisor
- Variation in root size of the lateral incisor
- Variation in timing of lateral incisor root formation
- Iatrogenic factors
- Idiopathic factors

### SYSTEMIC

- Endocrine deficiencies
- Febrile disease
- Irradiation

### GENETIC

- Hereditary
- Malposed tooth germ
- Presence of alveolar cleft



Brighter Futures is published by the Australian Society of Orthodontists (NSW Branch) Inc. in conjunction with the Orthodontic Discipline at the University of Sydney.

The newsletter is intended to help keep the dental profession updated about contemporary orthodontics, and also to help foster co-operation within the dental team.

Without the generous support of Henry Schein Halas and Colgate, who are an integral part of the dental team, this publication would not be possible.

---

*The statements made and opinions expressed in this publication are those of the authors and are not official policy of, and do not imply endorsement by, the ASO (NSW Branch) Inc or the Sponsors.*

---

Correspondence is welcome and should be sent to:

Department of  
Orthodontics  
University of Sydney  
Sydney Dental Hospital  
2 Chalmers Street,  
Surry Hills NSW 2010

---

## AUTHOR & EDITORS

Dr Sabrina Michael  
PRINCIPAL AUTHOR

Dr Chrys Antoniou  
Dr Dan Vickers  
Prof M Ali Darendeliler  
Dr Michael Dineen  
Dr Ross Adams  
Dr Susan Cartwright

[www.aso.org.au](http://www.aso.org.au)

## Treatment options

The treatment options available for impacted canines depend on a combination of factors:

- Patient age & developmental stage of the dentition.
- Position of the unerupted canine.
- Other features of the malocclusion that may also require treatment.
- Root resorption affecting the permanent incisors.
- Patient's perception of the problem and tolerance of orthodontic treatment<sup>30</sup>.

In some cases no treatment may be indicated if there is no associated pathology when orthodontic treatment is declined<sup>11</sup>. This can be the case where the deciduous canine is retained. In these cases regular monitoring of the impacted tooth is required and the patient must be informed of the poor prognosis for long-term retention of deciduous canines and the possibility of some pathology developing associated with the impaction.

Where active treatment is required, the two major options are removal of the impacted tooth or treatment to bring the impacted tooth into the dental arch. Removal of an impacted canine may be a suitable treatment option in the following cases:

- If it is ankylosed
- If it is undergoing external or internal root resorption
- If the root is severely dilacerated
- If the impaction is severe and where its movement will jeopardize adjacent teeth
- If the occlusion is acceptable with the first premolar in the position of the canine
- If there are pathologic changes (cyst formation or infection)
- Where no orthodontic treatment is wanted by the patient<sup>19</sup>
- Where removal and space closure, rather than canine traction, will be quicker, more comfortable and more practical.

An impacted canine can be repositioned into the arch by autotransplantation, however the long term success rate of this procedure is still not high. The most common treatment is surgical exposure of the canine using either an open or closed exposure followed by orthodontic traction to bring the canine into place.

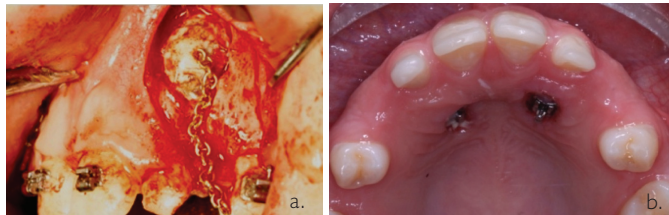


Figure 5: a) Surgical closure and placement of gold chain for closed exposure. b) Open exposure technique where the canines are allowed to spontaneously erupt.

There are many techniques for applying orthodontic traction to an impacted tooth including simple elastomeric and nickel titanium wires/coils to more complex appliances such as Burstone, Kornhauser and Whip springs. The technique chosen will depend on the direction and degree of force required to move the impacted tooth into the correct position without damaging the adjacent teeth<sup>1,11</sup>.

## Conclusion

Impacted canines are a common dental anomaly that has potential to damage the adjacent teeth in children as young as 9 years of age. Intervention and prevention are best achieved through early diagnosis and appropriate management. It is vital that early assessment of the eruption status of permanent canines is a routine part of all dental examinations in children. This can be readily incorporated into routine examination via the palpation for the unerupted tooth and visual assessment of the child's dental development from the age of 8. Where possible canine impaction is suspected further diagnostic tests, including radiographs, may be required. Early extraction of the deciduous canine is often indicated, however appropriate referral is recommended when active orthodontic management is necessary.

## References available upon request

 HENRY SCHEIN® | HALAS  
Everything Dental™

Your Dental One Stop Shop!