Australian Society of Orthodontists

University of Sydney

Deep bite Malocclusions

Creating Brighter Futures

Deep bite Malocculsions

Definition and Prevalence

Strang (1950) defined overbite as "the overlapping of the upper anterior teeth over the lowers in the vertical plane". More practically, due to the variable crown length of the incisors, Nanda & Upadhyay (2010) define deep bite as "the amount and percentage of overlap of the lower incisors by the upper incisors" . An ideal overbite ranges from 5-25% overlap.

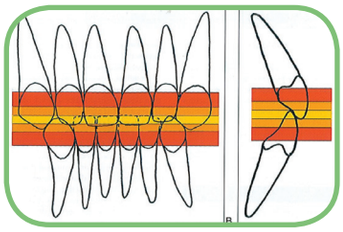

Fig. 1: Ranges of overbite. 5-25% normal (yellow), 25-40% increased (orange), >40% excessive (red). (Nanda & Kapila, 2010)

Fig. 2: Example of a severe deep bite.

The prevalence of severe deep bite varies between racial groups. For example, it is almost twice as common in Caucasian Americans compared to African Americans and Hispanics (Proffit 2007). From the NHANES data (Proffit 2007), 33.1% of cases had overbites of 3-4mm, with 14.2% having 5-7mm overbites. Overbites >7mm were seen in 1.7% of cases.

Tausche et al (2004) in their sample of 1975 Dresden children 6-8yrs found 46.2% had deep overbite (> 3.5mm) with or without gingival trauma, and 14.5% had complete traumatic overbite.

Aetiology and Diagnosis

Environmental and/or genetic factors play a role in the development of deep bites. Sassouni & Nanda (1964) described individual facial growth patterns to be genetically predetermined. Deep bites can be classified as skeletal, dental or soft tissue.

Skeletal Deep Bites: Also described as brachyfacial or hypodivergent facial pattern, skeletal deep bites exhibit characteristics including a reduced lower anterior face height, reduced mandibular plane angle and reduced gonial angle. Cephalometrically skeletal deep bites can also be seen to have an acute cranial base angle, reduced Jarabak ratio (proportion of posterior face height to anterior face height), reduced Y-axis, increased ramal length (Ngan & Fields, 1997), parallel Sassouni planes (Sassouni, 1969) and there is forward growth rotation of the mandible (Bjork, 1969). Nanda (1988) found that developmental growth occurs later in deep bite patients compared to open bite patients, and this may have implications in treatment timing. Deep bites are often associated with Class II malocclusions (Houston & Tulley 1986).

Dental Deep Bites: Over eruption of the incisors and or undereruption of the molars will result in excessive overbite (Prakash & Margolis 1952). Tooth loss can contribute to an occlusal imbalance resulting in lingual collapse of the anterior teeth and a deepening of the anterior bite (Bjork 1969; Upadhyay & Nanda 2010). Deep bites are commonly associated with an excessive Curve of Spee (Shannon & Nanda 2004). Tooth size discrepancies can also contribute to deep bites.

Soft Tissue Deep Bites: Deep bites are often associated with Class II malocclusions (Houston & Tulley 1986). Hypodivergent (short) facial patterns tend to have stronger mandibular elevator musculature and high mentalis activity (Proffit, 1983; Ingervall 1978), a deep mento-labial fold and everted lower lip.

Do deep overbites require correction?

If not treated, deep bites can result in trauma to the palatal mucosa behind the upper incisors or to the labial gingiva of the lower incisors (Proffit, 2007). This can result in painful soft tissue and periodontal defects. Nasry & Barclay (2006) found that traumatic bites in conjunction with poor oral hygiene could result in periodontal lesions, with gingival trauma and food impaction being important aetiological factors.

Colgate CARE COLUMN

Does toothpaste improve oral health?

Following 19 randomised controlled studies on the efficacy of triclosan copolymer toothpaste (Colgate Total), results showed over a period of 6 months brushing twice a day there will be clinically significant improvements in plaque control, gingivitis and a slower progression of periodontal disease.

Two groups of patients in need of special attention when it comes to oral health are:

- People with Diabetes
- Patients with implants

People with diabetes who do not control their illness optimally are twice as likely to develop periodontal disease as those people without diabetes. As a result, people with diabetes need to pay special attention to their oral hygiene and the products they use. Colgate Total toothpaste offers 12 hour antibacterial protection against dental plaque and can help fight gum disease when used regularly.

The gingival tissues around implants become inflamed by plaque biofilm similar to around teeth and 80% of patients with dental implants develop peri-implant mucositis. A randomised double-blind, parallel-group study was conducted with 59 patients who had at least 2 implants and at least 1 site with bleeding on probing as a symptom of perio-implant mucositis. These patients brushed twice daily with Colgate Total or regular fluoride toothpaste. Results showed that gingivitis was significantly reduced in sites with dental implants when brushed with Colgate Total compared to regular fluoride toothpaste ($p<0.001$).

So does toothpaste improve oral health? Evidence shows the answer is a resounding YES – in particular when a triclosan copolymer toothpaste such as Colgate Total is used.

REFERENCES:

1. Blinkhorn A et al. BDJ 2009; 207(3):117-125
2. Mealey BL and Ocampo GL. Periodontol 2000 2007; 44: 127-153
3. Lindhe J and Meyle JJ Clin Periodontol 2008; 35 (suppl 8): 282-285.
4. Ramberg P et al. J Clin Dent 2009; 20: 103-107.

COLGATE IS THE PREFERRED BRAND OF THE ASO NSW

Fig. 3: Extreme example of labial gingival trauma from deep bite and associated periodontal defects.

Excessive attrition of anterior teeth, especially lower incisors, is often associated with a deep anterior overbite and bruxism. Correction of the deep anterior overbite will not stop the bruxism, but should reduce the rate of attrition.

Helm & Peterson (1989) in their study of 176 adolescents who were re-examined at age 40 found those with increased overbite and overjet had increased DFS (decayed or filled surfaces) on the maxillary incisors.

Fig. 4: Examples of early incisal wear related to deep bite

Nanda (1981) classifies overbites greater than 40% as excessive, compromising the periodontal tissues and acting as a co-contributing factor in the aetiology of TMD. Thompson (1986) and Farrar & McCarty (1983) hypothesised that steep incisal guidance could result in abnormal TMJ movements due to posterior condylar displacement. However, later studies disagree. Gianelly et al (1989) found there was no significant correlation between bite depth and condylar position. Egermark-Eriksson et al (1990), in their study of 238 subjects comprising children and adolescents followed over 4-5yrs, found only low associations between cranio-mandibular disorders and different morphological malocclusions. Pullinger & Seligman (1991), in their regression analysis of risk and relative odds of TMD as a function of occlusal features, found deep overbite was not considered to contribute to TMD.

Treatment modalities

Orthodontic treatment mechanics to correct a deep bite must be specific for the type of deep bite and etiological factors identified in the diagnosis for each individual patient. The amount of growth remaining also affects treatment decisions and modalities.

1. Intrusion of upper and or lower incisors

Absolute intrusion involves moving the dentition deeper into bone and can be used in both adolescent treatment and adult orthodontic treatment where there is no growth (Proffit, 2007). Bypass and segmental mechanics are methods for absolute intrusion to apply light continuous forces in an apical direction. This can be accomplished by for example Begg, Mulligan bypass arches, Rickett's utility arches or Burstone segmented arch wire techniques.

Fig. 5: Bypass intrusion arch

The bypass arch is a continuous arch wire that bypasses the premolars (and often canines) to maintain light forces by lengthening the span between molars and incisors. Although this method can be used for adults it is more effective for patients with growth remaining (Proffit, 2007).

Today, en masse intrusion of all anterior teeth is possible using temporary skeletal anchorage (Melsen et al, 1990) without relying on traditional, compliance dependent extra-oral appliances, or less predictable segmental intrusion mechanics.

Fig 6: Temporary skeletal anchorage used for en masse intrusion and distallisation.

Relative intrusion is where incisor eruption is impeded while the posterior teeth are free to erupt passively, particularly with the assistance of mandibular growth (Proffit, 2007). Methods of relative intrusion include Anterior Bite Plates contacting the anterior dentition while allowing posterior eruption; and, Twin-Blocks, where differential molar eruption can occur by trimming the posterior blocks. Treatment timing is important, ideally undertaken in the actively growing pubertal child at cervical maturation stage 3/4 (Baccetti et al, 2005).

Fig. 7: Example of a bite-plate reducing a deep bite.

Australian Society of Orthodontists

Brighter Futures is published by the Australian Society of Orthodontists (NSW Branch) Inc. in conjunction with the Orthodontic Discipline at the University of Sydney.

The newsletter is intended to help keep the dental profession updated about contemporary orthodontics, and also to help foster co-operation within the dental team.

Without the generous support of Henry Schein Halas and Colgate, who are an integral part of the dental team, this publication would not be possible.

The statements made and opinions expressed in this publication are those of the authors and are not official policy of, and do not imply endorsement by, the ASO (NSW Branch) Inc or the Sponsors.

Correspondence is welcome and should be sent to:

Department of Orthodontics
University of Sydney
Sydney Dental Hospital
2 Chalmers Street,
Surry Hills NSW 2010

AUTHOR & EDITORS

Dr Kitirat Jippy Buck
PRINCIPAL AUTHOR

Dr Chrys Antoniou
Dr Dan Vickers
Prof M Ali Darendeliler
Dr Michael Dineen
Dr Ross Adams
Dr Sarah Raphael

www.aso.org.au

2. Extrusion of upper and or lower posterior teeth

Active extrusion of the posterior teeth results in an increase in lower anterior face height (Proffit, 2007), generally associated with a downward and backward rotation of the mandible. This can be undesirable in some skeletal Class II cases; however in more hypodivergent cases it is often advantageous. Cervical head gear and inter-maxillary elastics are commonly used to achieve posterior extrusion.

3. A combination of anterior intrusion and posterior extrusion

Commonly used this can be achieved by placing anterior brackets more incisally and posterior brackets more gingivally or by using reverse-curve archwires (Upadhyay & Nanda, 2010). Mechanical control is not precise and side effects can include altered axial inclination of posterior teeth and proclined incisors from applying intrusive forces anterior to the centre of resistance of the teeth. Overbite reduction by levelling the Curve of Spee using continuous arch wires with reverse curves usually produce more extrusion of posterior teeth and negligible intrusion of anterior teeth.

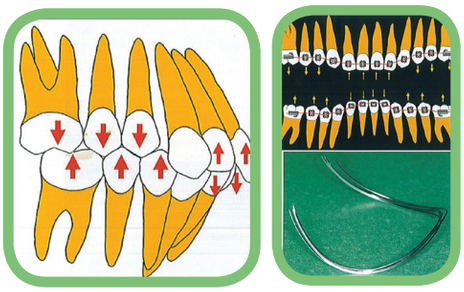

Fig. 8: Deep bite correction by incisor intrusion and posterior extrusion by use of reverse-curve archwires (Nanda & Kapila, 2010)

4. Proclination of incisors

Parker, Nanda & Currier (1995) found that with most mechanics deep bite correction mainly occurred by incisor proclination and extrusion of molars. However excessive proclination may lead to labial recession in thin gingival biotypes. As a general principal, treatment mechanics and stability of overbite reduction are enhanced if extractions are avoided in deep bite cases.

5. Adult surgery

In severe adult skeletal deep bite cases, orthognathic surgery is an option to increase the efficiency of orthodontic mechanics, improve facial aesthetics and enhance long-term stability (Bell et al, 1984). Surgical options include mandibular advancement, maxillary surgery and sub-apical osteotomy.

Conclusion

Deep anterior bites are a common problem amongst patients with correction of deep overbites often a strong functional indication for orthodontic treatment. Uncorrected deep bites may lead to loss of tooth structure due to attrition, as well as periodontal compromise due to traumatic occlusion and impingement. It is important to assess the patient facially, skeletally and dentally to ensure correct diagnosis of the vertical dimension. Identification of the aetiology of the deep bite will allow formulation of appropriate treatment mechanics.

References available on request

HENRY SCHEIN® | HALAS
Everything Dental™

Your Dental One Stop Shop!