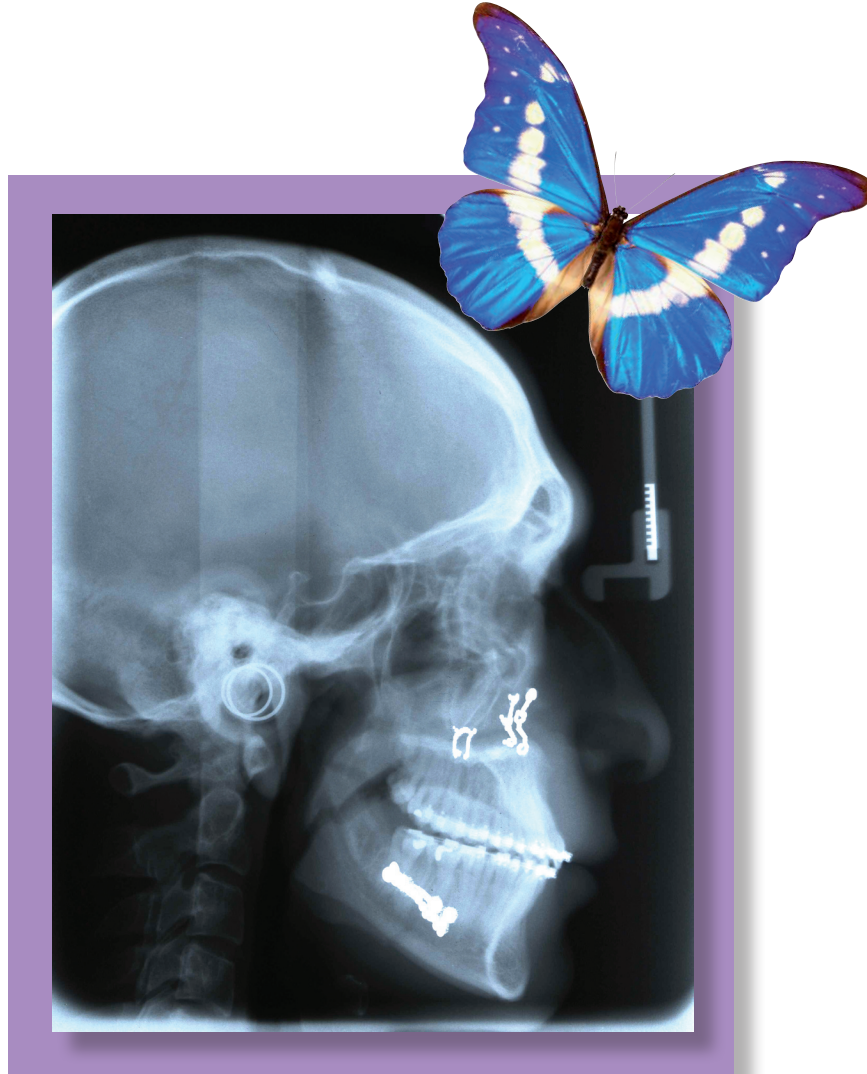


Australian Society
of Orthodontists



University of Sydney



Orthognathic Surgery & Orthodontics

PART 2

Creating Brighter Futures

Orthognathic Surgery & Orthodontics

Introduction

Part 1 of **Orthognathic Surgery and Orthodontics** in the **2008-1** issue of **Brighter Futures** covered the basics of surgical-orthodontic correction of skeletal malocclusions and dentofacial deformities, including indications for orthognathic surgery, treatment planning, surgical procedures and surgical fixation. Part 2 of **Orthognathic Surgery and Orthodontics** will elaborate on specific clinical implications including orthodontic treatment requirements, surgical splints and post-operative consequences.

Model surgery & surgical splints

Accurate treatment planning for surgical jaw movements involves comprehensive records including clinical examination, photographs, radiographs and study models. These allow consistent communication between the orthodontist, maxillofacial surgeon and other members of the dental team to formulate the Surgical Treatment Objectives (STO) or the Visual Treatment Objectives (VTO). The STO or VTO can be drawn manually or with the assistance of computer software. In addition the surgical jaw movements are simulated on mounted study models and these then serve as the template for fabrication of the surgical splint.

The surgical splint is a wafer of occlusal acrylic used during surgery to accurately reposition the maxilla and/or mandible. Once the surgeon has made the osteotomy cuts the splint is positioned over the patient's dentition and wired into place prior to placement of rigid fixation plates and screws securing the surgical jaw movements. If bimaxillary surgery is planned, a second surgical splint will be required to complete the second surgical jaw movement.

Orthodontic treatment requirements

Pre-surgery orthodontics

The objective of the pre-surgical orthodontic phase of treatment, which may take anywhere from 6 to 18 months, is to eliminate the dental compensations that have developed due to the skeletal discrepancy. In addition space closure, tooth alignment and general arch co-ordination is usually also undertaken. The teeth are positioned ideally within their respective alveolar processes so that following surgical jaw repositioning optimal alignment and occlusal co-ordination is achieved.

For example, orthodontic decompensation for skeletal Class II malocclusions will typically involve retraction of protruded upper and lower incisors including labial root torque of these incisors. This may also require the extraction of some premolars to provide space if the required retraction is significant.

Skeletal Class III malocclusion decompensation also often requires labial root torque for the upper incisors. The lower incisors usually require lingual root torque and proclination to correct the compensatory retroclination that is often present.

Arch co-ordination should usually include occlusal plane levelling in order to establish a normal overbite once the jaws are surgically repositioned. Poor arch co-ordination, particularly in the transverse or vertical plane, will restrict or destabilize jaw movements at the time of surgery and compromise post-surgical stability.

Precise orthodontic tooth movement may be required for segmental jaw surgery to create space between teeth for the surgical cuts. This may also require divergence of roots of these teeth.

Post-surgery orthodontics

During the initial post-surgery healing phase, orthodontic appliances provide anchorage for intermaxillary elastic traction to support and augment the surgical correction. Active orthodontic treatment following surgery should ideally be limited to detailing the occlusion to satisfy optimum aesthetic and functional requirements. There can be some skeletal relapse following surgery that can be camouflaged or compensated by appropriate orthodontic treatment mechanics, thereby maintaining an optimal treatment result.

Comprehensive treatment planning and precise pre-surgery orthodontics are vital to ensure minimal post-surgery orthodontics. Studies have shown that a long post-surgery orthodontic phase is one of the major causes of patients' dissatisfaction with treatment.

Post-surgery recovery

Oral hygiene. Tooth brushing is particularly difficult during the first week post surgery. However patients should be instructed that meticulous oral hygiene is essential to prevent infections and promote healing. Appropriate instruction should also be given regarding warm salt water and chlorhexidine



The Oral Health – Systemic Health Relationship

The link between oral health and systemic disease is not new and from ancient times teeth were implicated in many different systemic diseases. As early as 2000BC The Egyptians associated tooth pain with disease in the reproductive system. In 1890-91, Miller (Dental Cosmos 33: 689-713) published "Micro-organisms of the human mouth" and "The human mouth as a focus of infection" which outlined the basis of dental caries and implicated oral pathogens in systemic diseases including gangrene, noma, tuberculosis, syphilis, pneumonia, meningitis and many others. As the medical profession became aware of Miller's work the concept of "focal infection" became popular. His findings led to public oral hygiene campaigns and also many physicians referred patients to have all of their teeth removed in the belief that oral infections caused many medical ailments.

The "focal infection" theory fell out of favour by the early 1950's as systemic disease symptoms were found not to be relieved by exodontia and there was very little interest in the relationship of oral disease and systemic disease, with the exception of infective endocarditis. In 1989, with the publication of "Association between dental health and acute myocardial infarction." by Matilla et al. (BMJ 298: 779-82) a new era of understanding was launched. This study was one of the first of many studies which began to investigate the association of periodontal disease and systemic disease. In 2007 the World Health Organisation Executive Board on Oral Health acknowledged the intrinsic link between oral health, general health and quality of life. In the next four Colgate Care Columns we will explore the evidence for Periodontal Disease as a risk factor for – Diabetes, Cardiovascular Disease, Adverse Pregnancy Outcomes and Pulmonary Disease.



mouthwashes. Resorbing sutures are usually used and this aids oral hygiene.

Diet. Post-surgery nutrition initially may be restricted to a liquid and pureed diet followed strictly by soft foods then a gradual return to normal diet. Adequate fluid intake should be maintained throughout the healing phase.

Recuperation. Patients should be advised to take at least two to three weeks leave for single jaw surgery and three to four weeks leave for two jaw surgery from work or school, although, depending on the procedures involved, healing and recovery times may vary.

Appearance. Patients should be cautioned prior to surgery regarding the potentially significant impact of post-surgical swelling and haematoma on their appearance. Soft tissue recovery can still be occurring up to 6 months after surgery. Psychologically, research has shown, patients tend to have an emotional decline within the first week after surgery, however by the 6th week they are happier with their appearance than before surgery. Pre-surgical advice and re-assurance should emphasize that varying emotional responses post-surgery are considered within normal behavioural limits.

Complications

There is some risk associated with all surgical procedures. Although complications following orthognathic surgery are uncommon, patients should be comprehensively informed of risks involved. General surgical risks include side effects from general anaesthesia, infection, scarring and inflammation of veins. Other problems associated with orthognathic surgery include:

Pain. Usually most intense during the first two or three days after surgery, but is controlled with pain relief medications, which may be required for seven to ten days.

Blood loss. With modern techniques of hypotensive anaesthesia and shorter operating times, blood loss is now minimal and blood transfusion is not often required. However, autologous blood donation may be recommended for more complex bimaxillary surgical cases.

Swelling. Can be expected to peak after 48 hours. Most swelling will subside after 14 days with residual swelling usually resolved after three to four weeks.

Bruising. Can occur over the face, neck and chest as swelling subsides, and usually disappears after seven to ten days.

Nerve Damage. Temporary loss of sensation involving the chin and lower lip in particular is not uncommon with mandibular surgery. This usually lasts 3 to 12 months, but can be permanent in approximately 5% of cases.

Nasal sinus. Will be affected or congested for several weeks after maxillary surgery.

Limited facial movement. Is inevitable following facial surgery due to swelling and mainly involves restricted mouth opening. Elastic bands are used for support and to guide the lower jaw into occlusion. Jaw function will usually return to normal after four to six weeks.

Fixation. Loose or prominent bone screws or plates used for rigid fixation do very occasionally occur and may require removal and further surgery.

Bone healing. Delayed union or non-union of bone is rare in healthy patients and these problems can normally be corrected using bone grafts. Smoking increases the risk of poor bone healing. Rare instances of maxillary bone necrosis have been reported when the maxilla has undergone multiple sectioning as well as down fracturing

Relapse. Although significant relapse of surgical correction is not common, minor relapse is. Overcorrection of jaw movements is often incorporated in the treatment plan to compensate for this. The use of elastic traction post-surgically also helps to reduce this relapse.

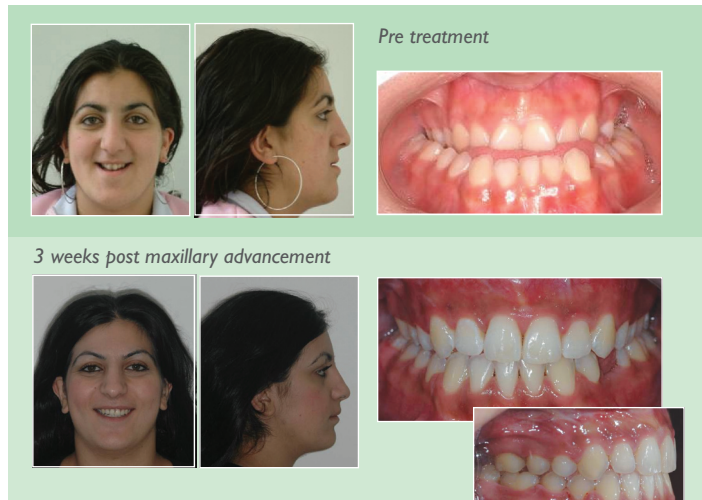
Loss of teeth. Is very rare but can occur where the surgery site inadvertently involves roots of teeth.

TMD. Surgery can aggravate or exacerbate existing TMJ problems and require further management.

Case Reports

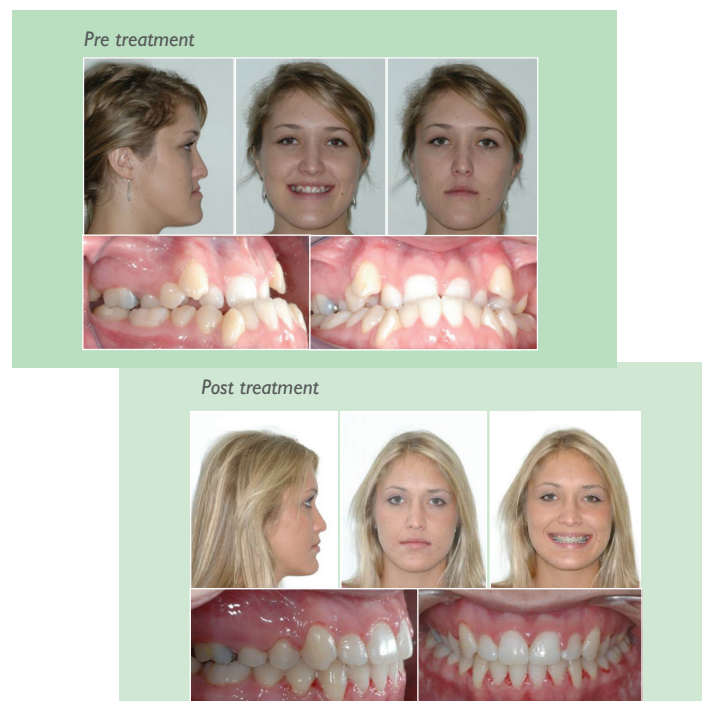Case 1 - Surgically Assisted Rapid Maxillary Expansion and Maxillary Surgery

This 21yr old patient was diagnosed with a transverse maxillary deficiency and a Class III skeletal base due to maxillary retrusion. The orthodontic and surgical treatment plan included a first phase of surgical assisted maxillary expansion, followed by 15 months of presurgical orthodontics to decompensate the arches. A maxillary advancement was then undertaken followed by 12 months of post-surgical detailing.



Case 2 - Bimaxillary Surgery

This 18yr old patient was diagnosed with a maxillary transverse deficiency, a Class III malocclusion on a skeletal III base (maxillary retrognathism, mandibular prognathism). Her combined orthodontic and surgical treatment plan consisted of initial surgically assisted rapid maxillary expansion, followed by orthodontic decompensation. A bimaxillary procedure was then carried out (maxillary advancement, mandibular setback), followed by post-surgical orthodontics and retention.



Brighter Futures is published by the Australian Society of Orthodontists (NSW Branch) Inc. in conjunction with the Orthodontic Discipline at the University of Sydney.

The newsletter is intended to help keep the dental profession updated about contemporary orthodontics, and also to help foster co-operation within the dental team.

Without the generous support of Henry Schein Halas, 3M Unitek and Colgate, who are an integral part of the dental team, this publication would not be possible.

The statements made and opinions expressed in this publication are those of the authors and are not official policy of, and do not imply endorsement by, the ASO (NSW Branch) Inc or the Sponsors.

Correspondence is welcome and should be sent to:

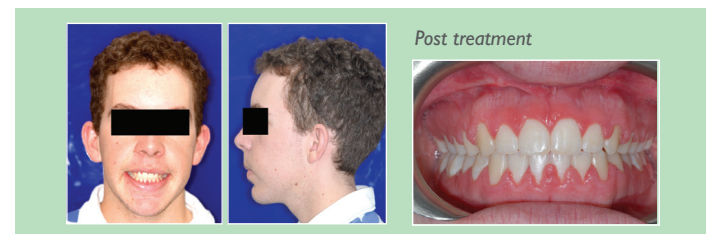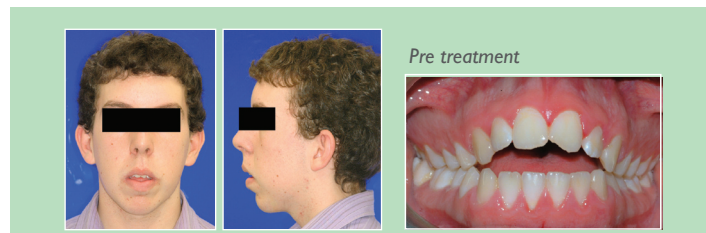
Department of
Orthodontics
University of Sydney
Sydney Dental Hospital
2 Chalmers Street,
Surry Hills NSW 2010

AUTHOR & EDITORS

Dr Gosia Kluczewska
PRINCIPAL AUTHOR
Prof M Ali Darendeliler
Dr Dan Vickers
Dr Michael Dineen
Dr Ross Adams
Dr Paul Taylor
Dr Lydia Lim
Dr Sarah Raphael

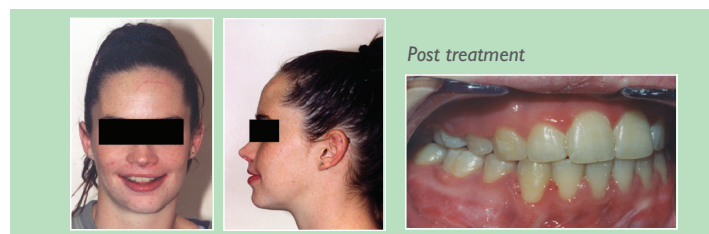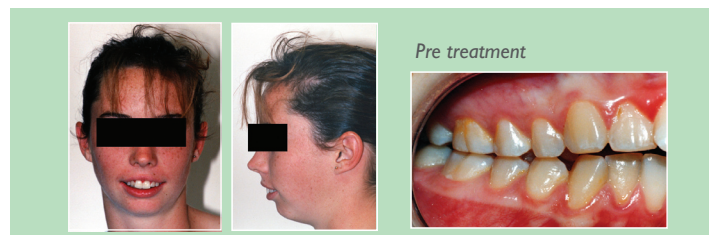Case 3 - Maxillary Impaction and Advancement Genioplasty

This 18 year old patient had a Class I malocclusion with a receding chin and vertical facial growth helping to produce an anterior open bite. Following orthodontic decompensation and alignment of the teeth the surgical treatment consisted of maxillary impaction, 8mm posteriorly and 5mm anteriorly. This allowed the mandible to auto rotate up and forwards to close the open bite. A genioplasty to advance the chin 8mm was also undertaken to improve facial appearance.



Case 4 - Mandibular Advancement and Advancement Genioplasty

This patient had a Class II malocclusion with significant mandibular retrognathism. Following orthodontic decompensation and alignment of the teeth the surgical correction consisted of mandibular advancement and advancement genioplasty to achieve a satisfactory occlusion and pleasing facial appearance.



References available on request

 HENRY SCHEIN® | HALAS
Everything Dental.™

Your Dental
One Stop Shop!

 3M Unitek
Products that make your life easier

www.aso.org.au